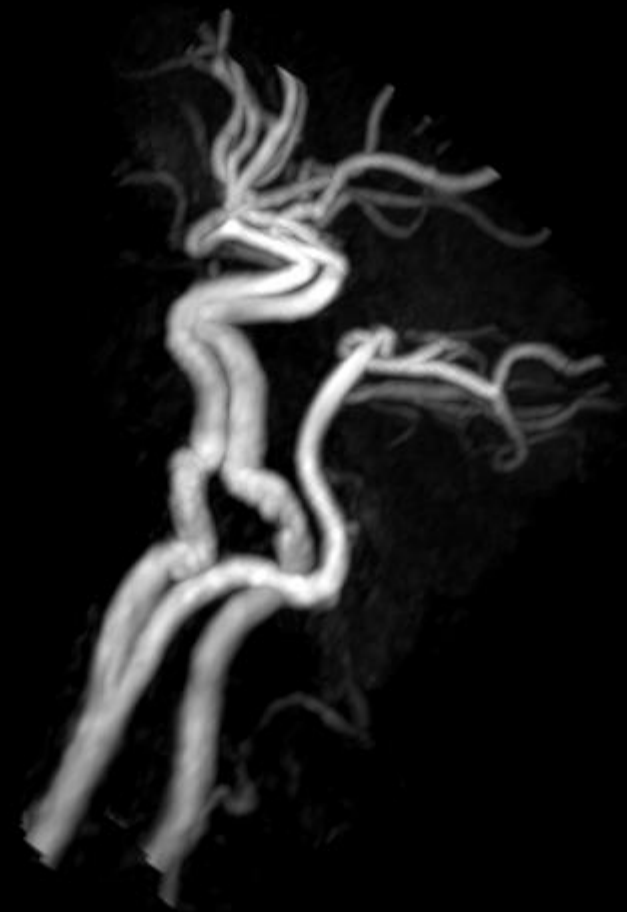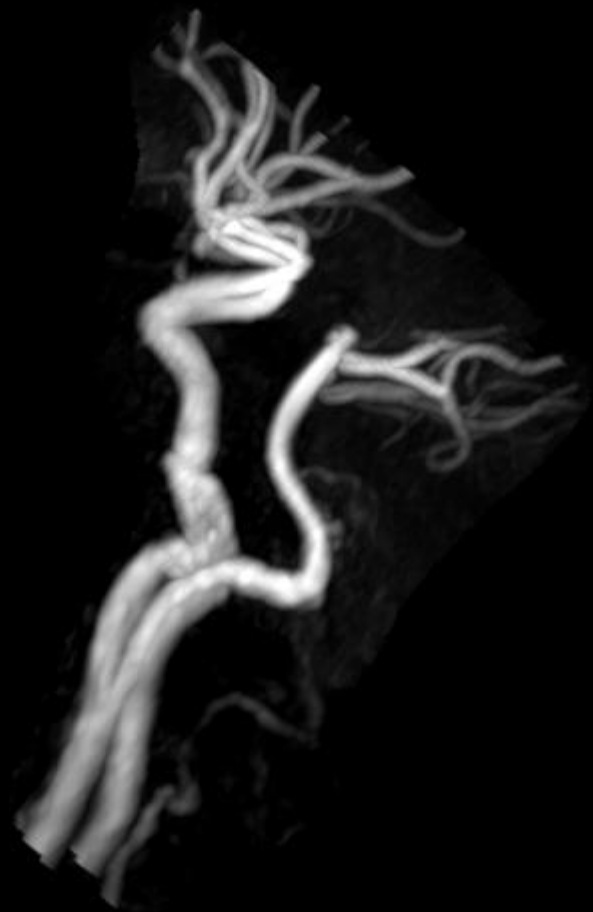

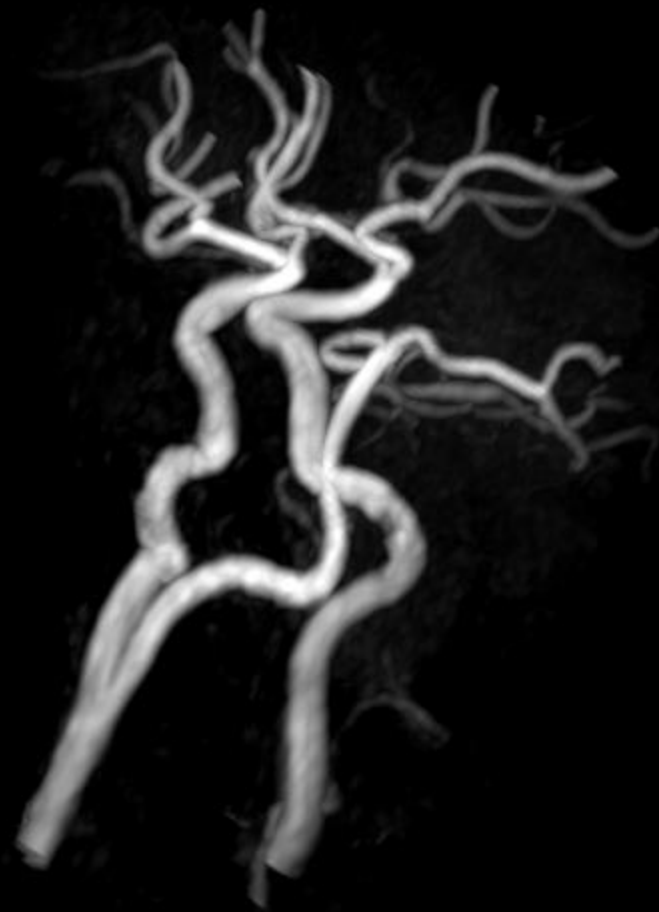
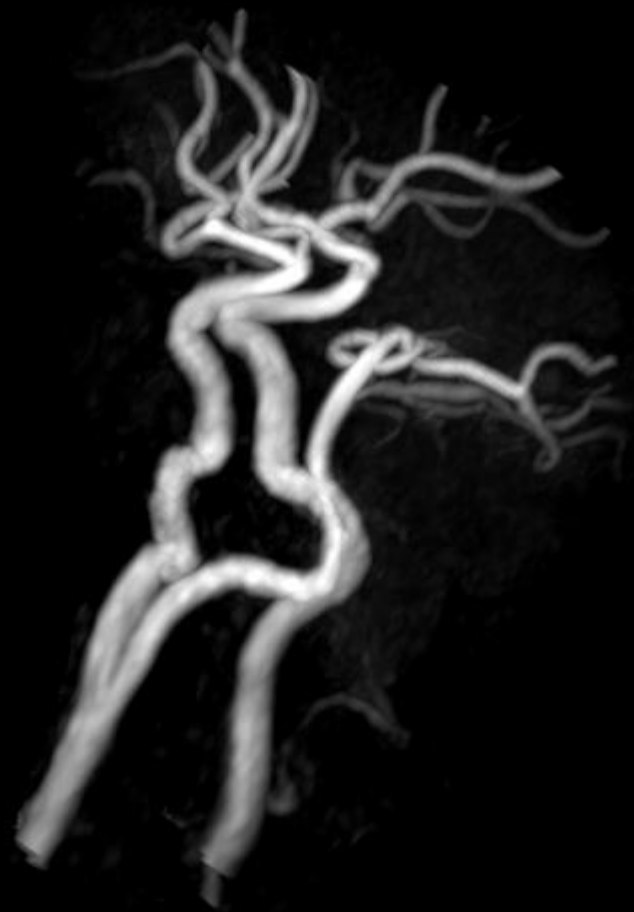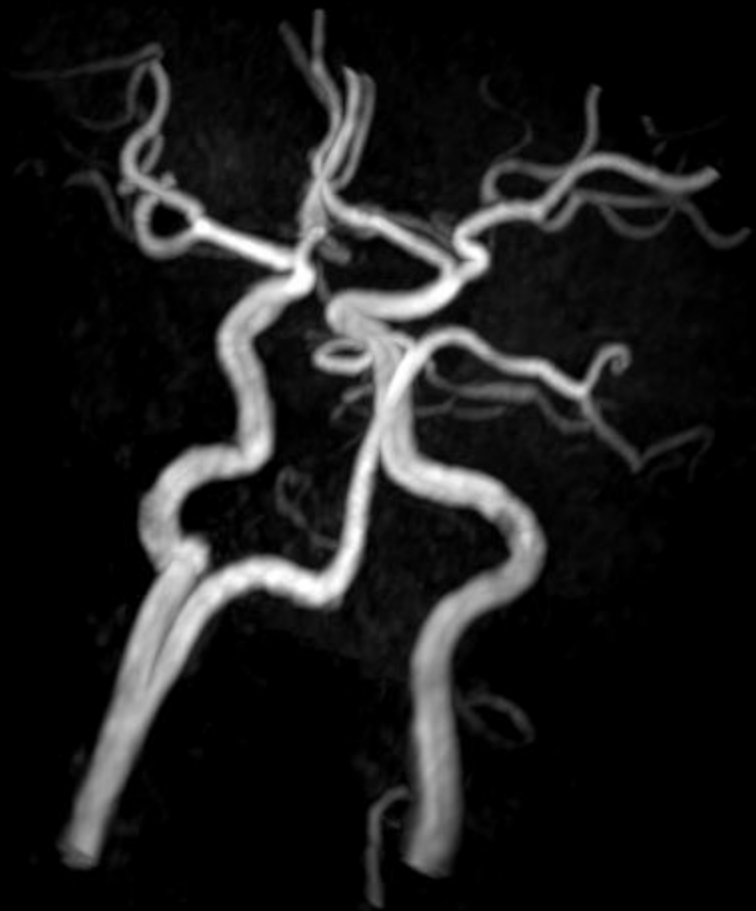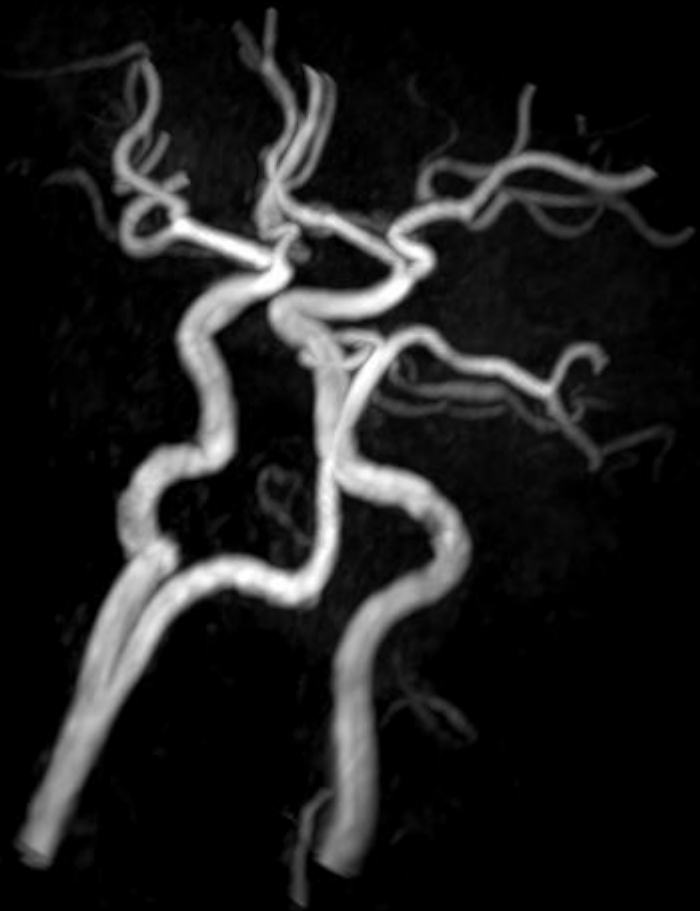A 9-year-old girl

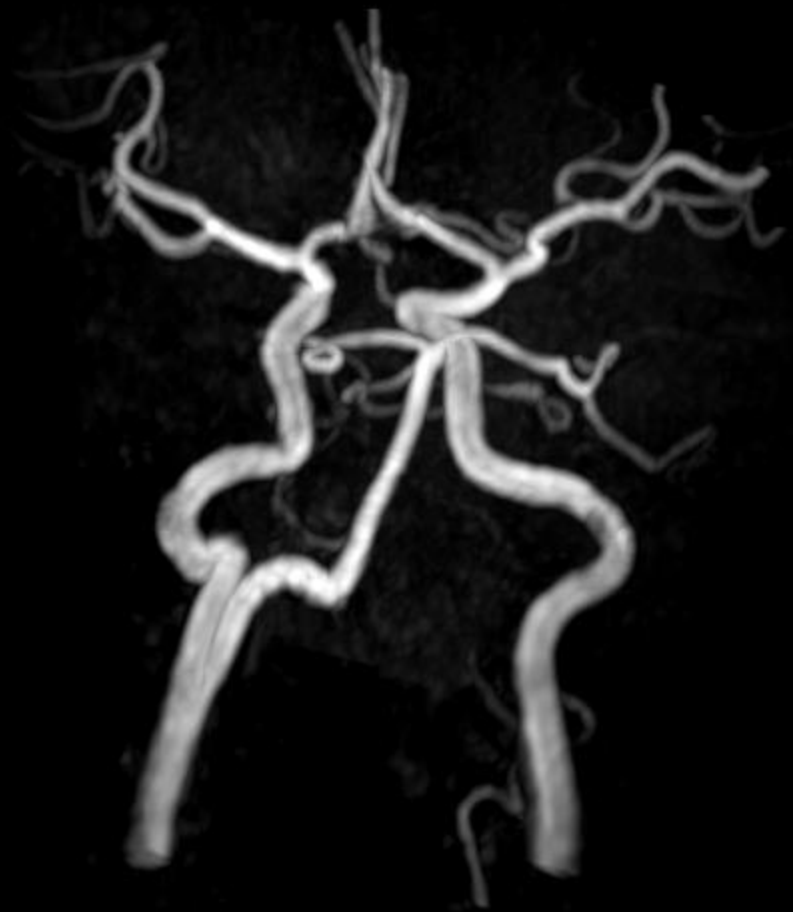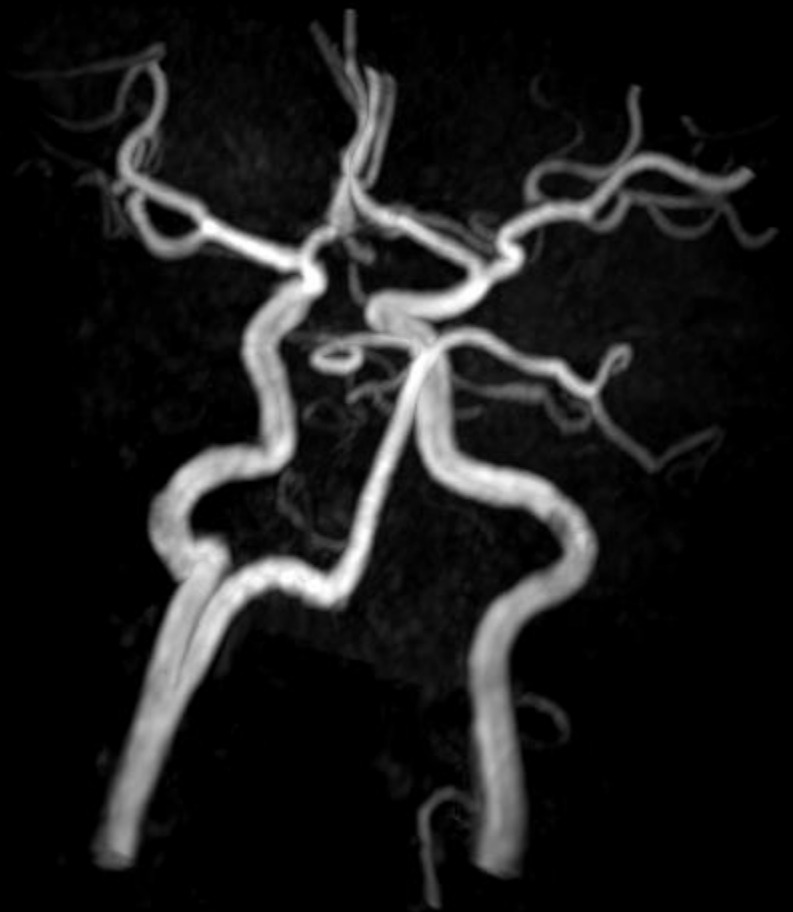Tetralogy of Fallot, Congestive heart failure
Cerebral infarctions

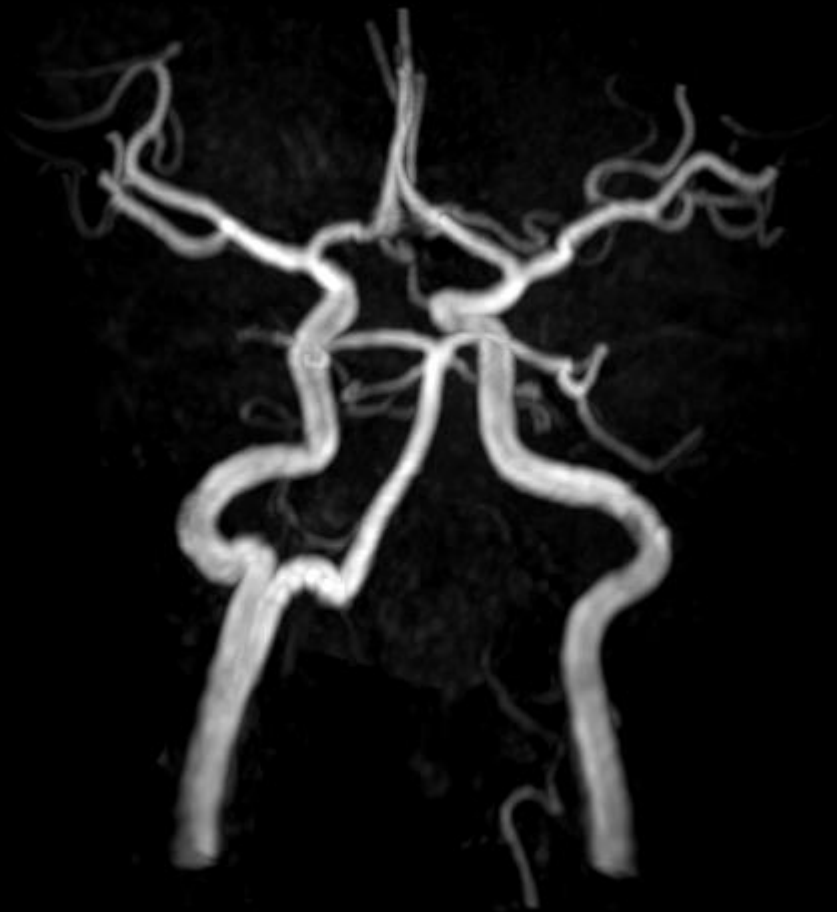There are 3 kinds of cerebral arterial variation.





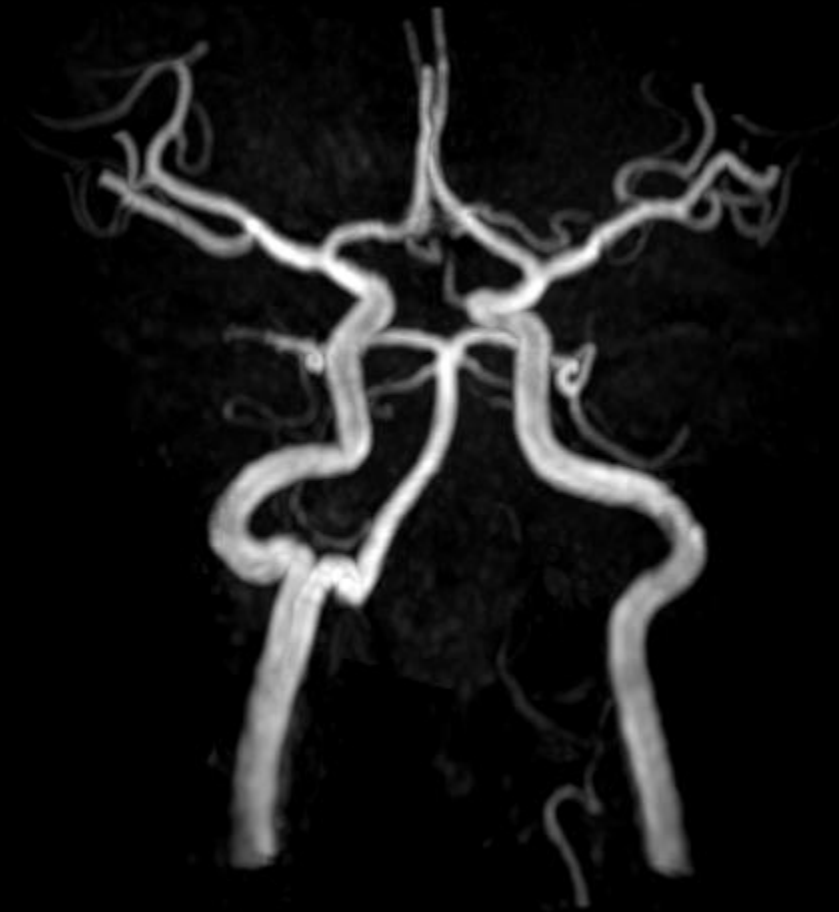





ページ: 9 of 19

IM: 9 SE: 105



ページ: 10 of 19

IM: 10 SE: 105









