

症例5-6

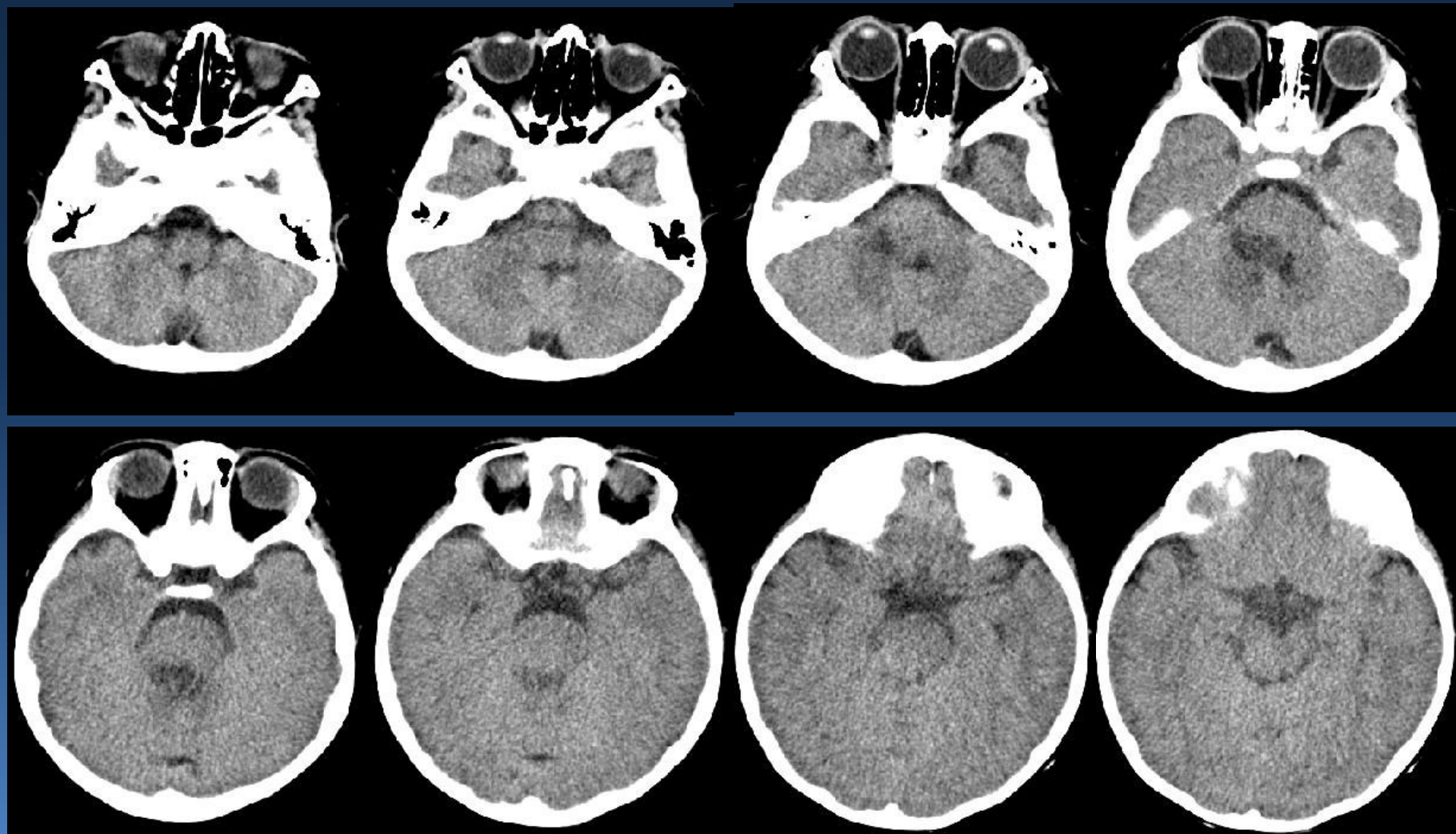
島根大学 症例

島根大学医学部 放射線医学講座
勝部 敬、北垣 一

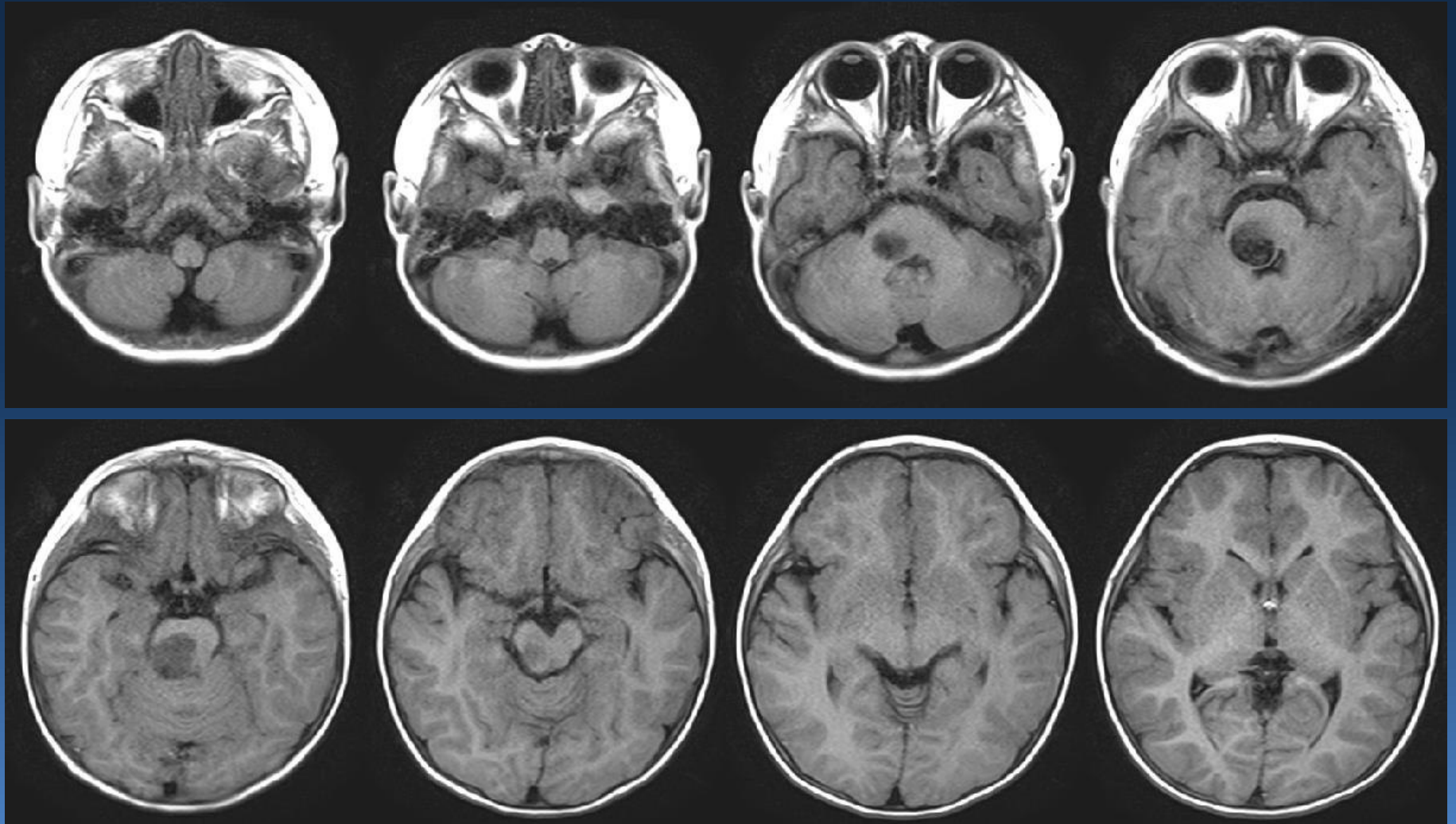
Case

- 2歳 男児
- 主訴：ふらつき歩行
- 現病歴：一ヶ月前から歩行時のふらつきあり、徐々に顕著になってきた。また、笑った時などに顔のゆがみも出現してきた。
- 既往歴：特になし
- 2-year-old boy
- Chief complaint:
 - Walking with a stagger
- Present illness:
 - He increasingly walked with a stagger for a month and recently laughed with facial distortion.
- Previous medical history:
 - Nothing particular

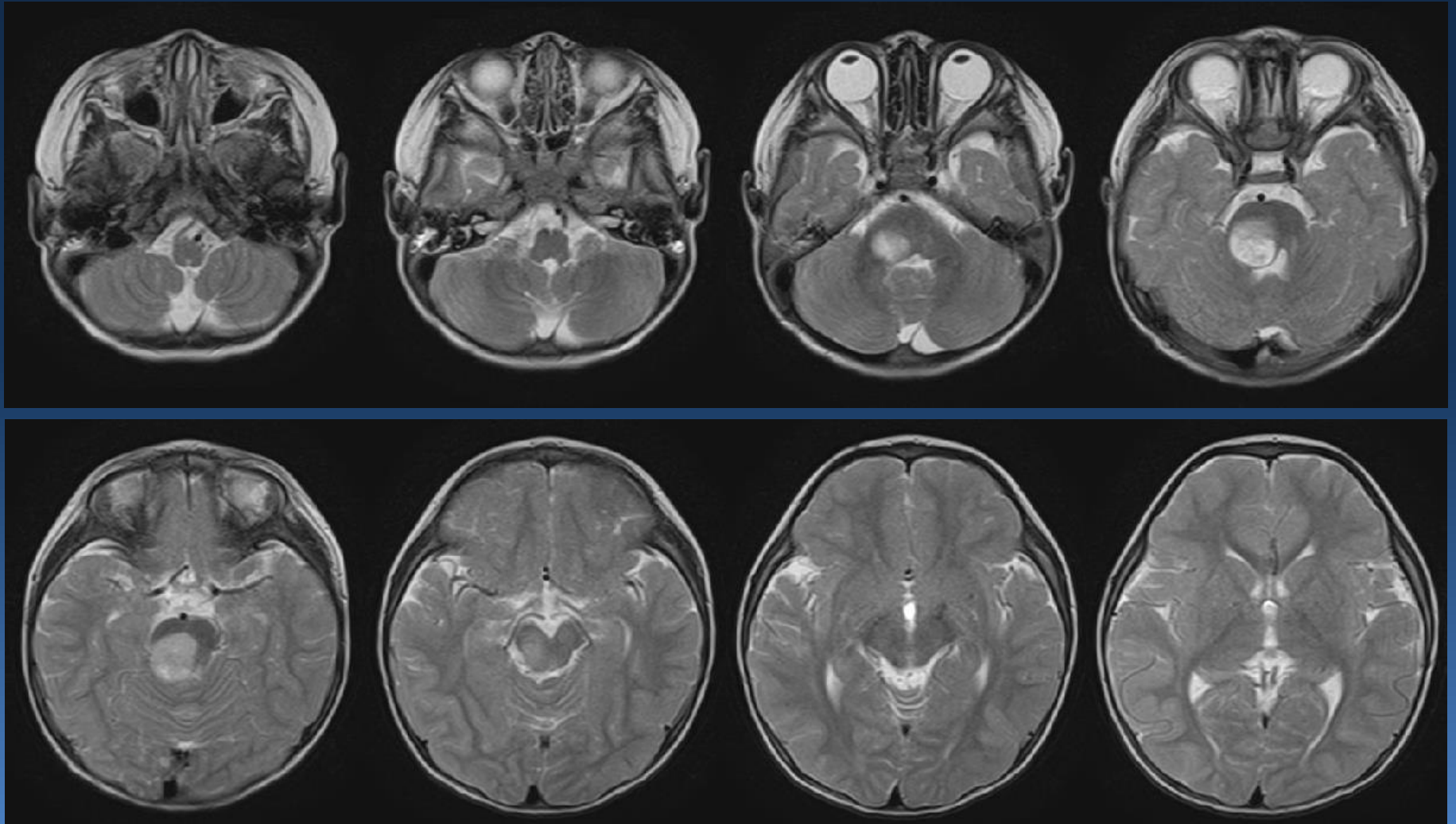
Plain CT



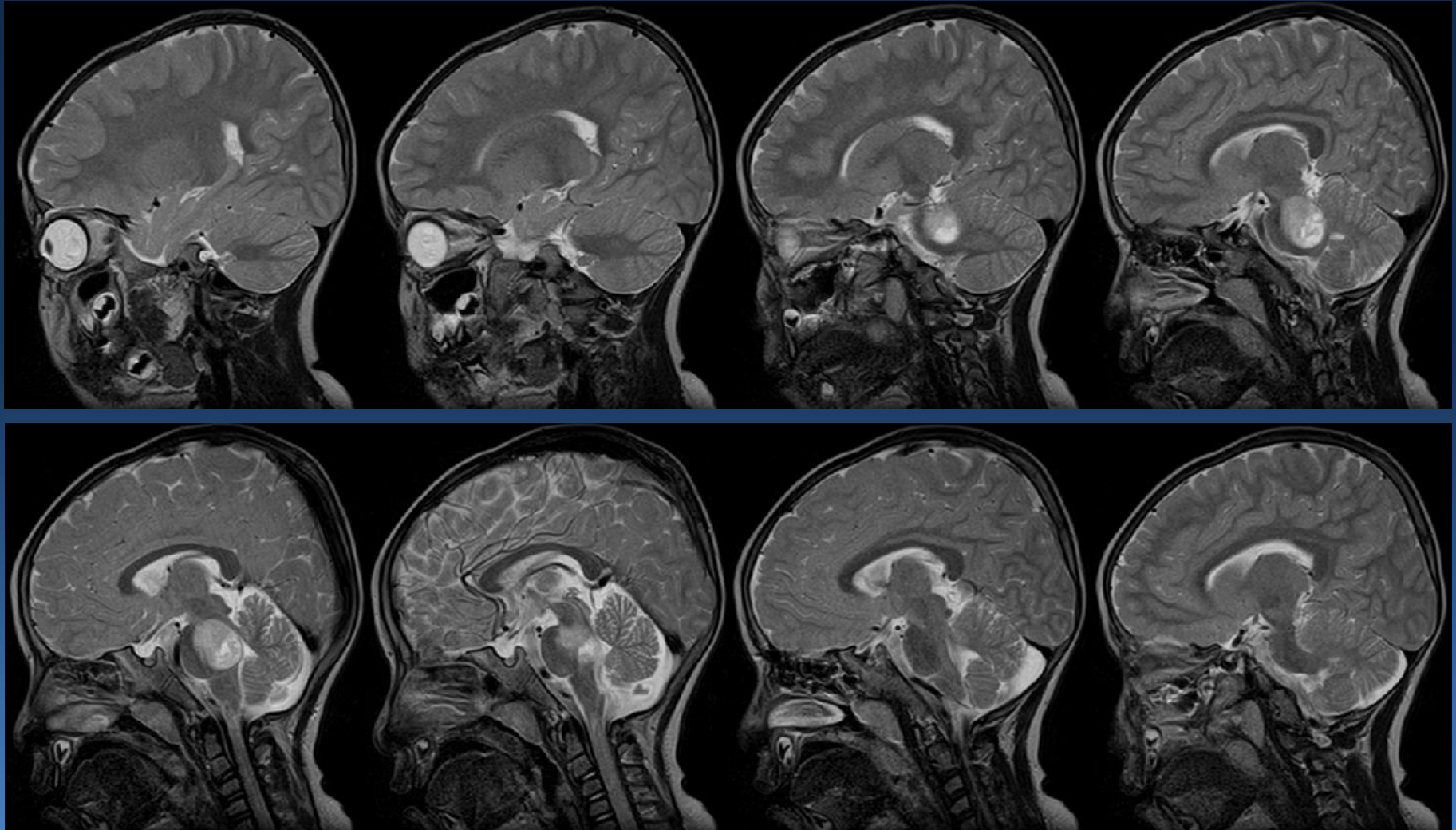
T1WI



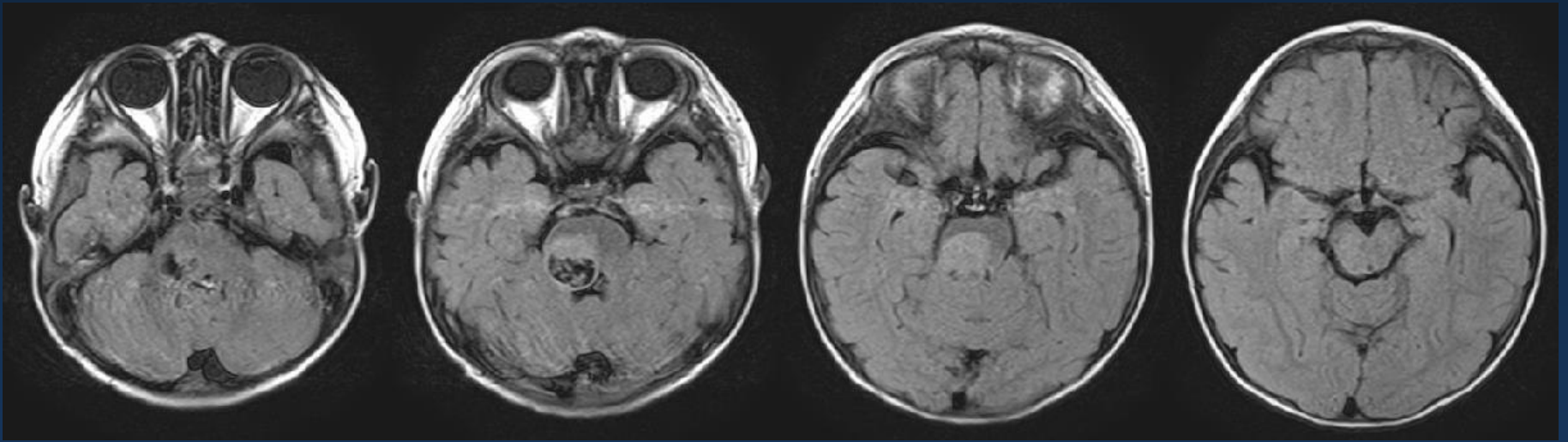
T2WI



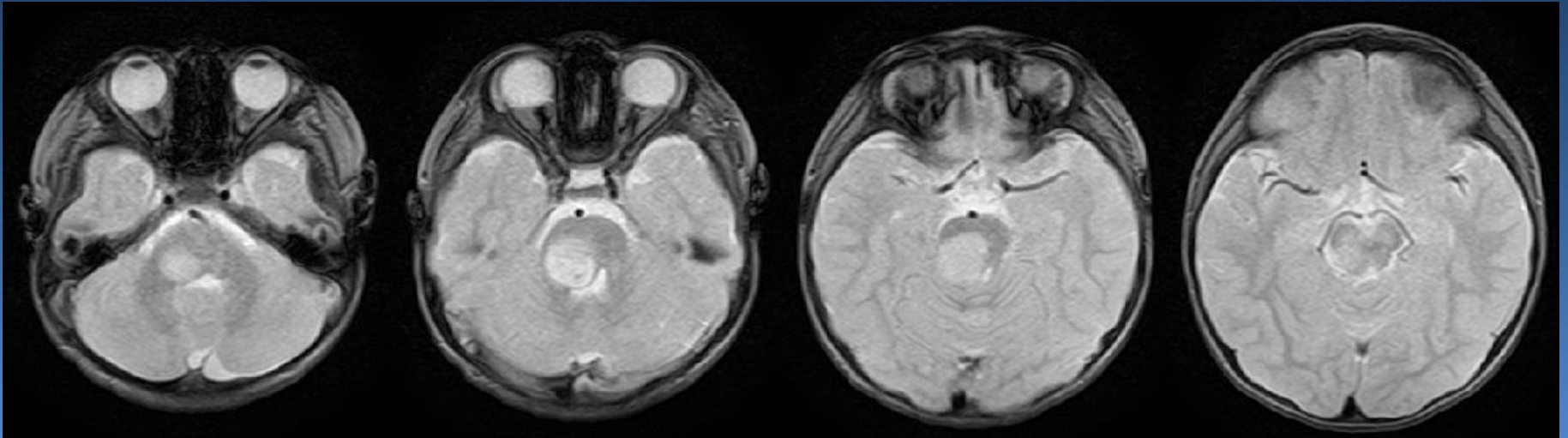
T2WI sagittal



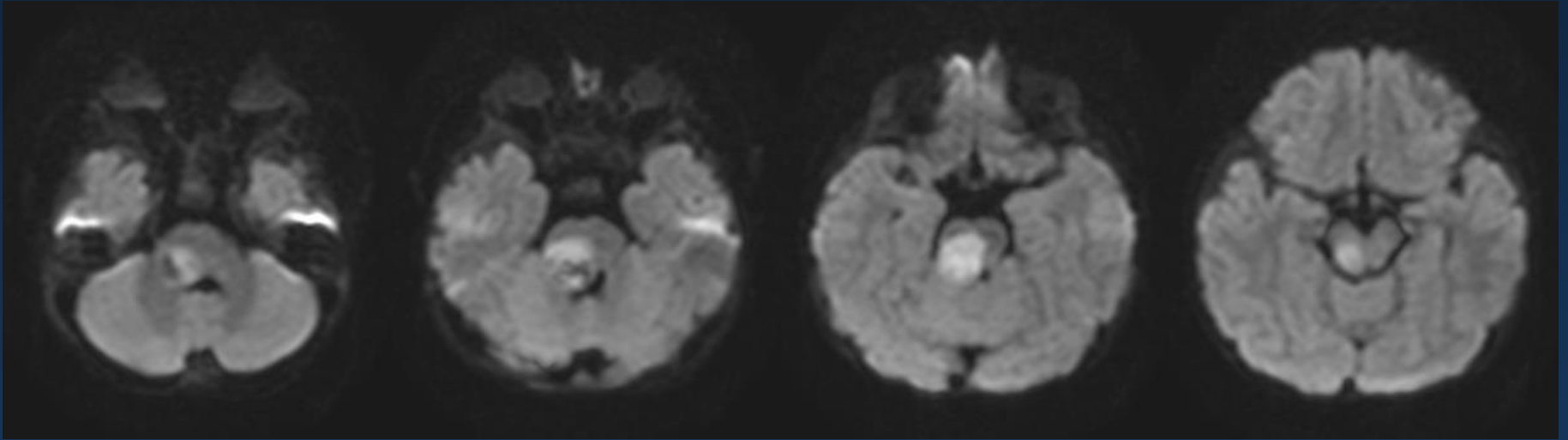
FLAIR



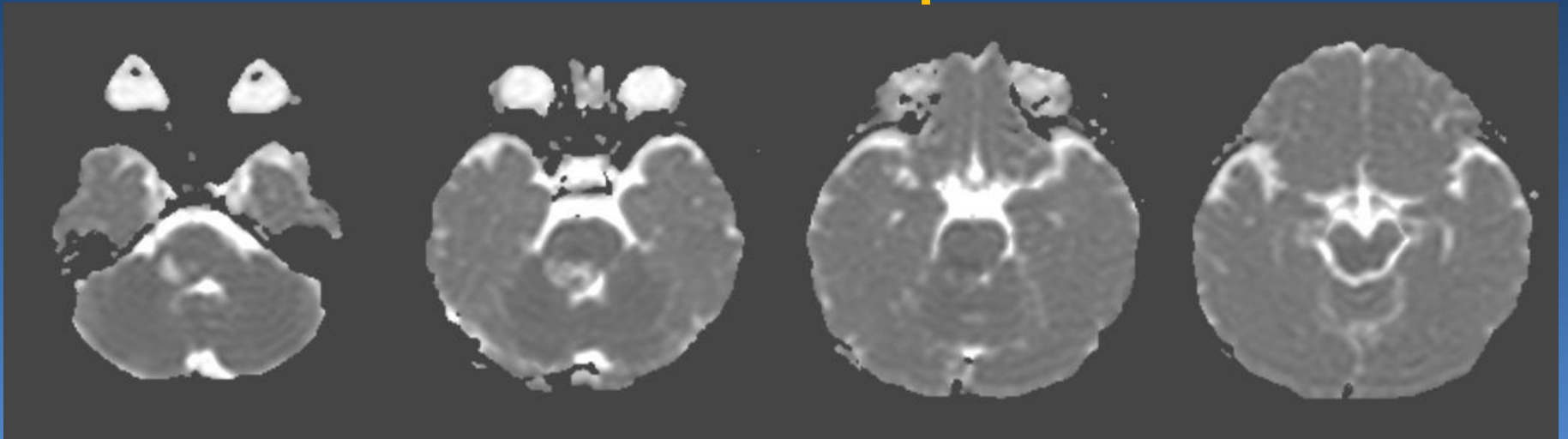
T2*WI



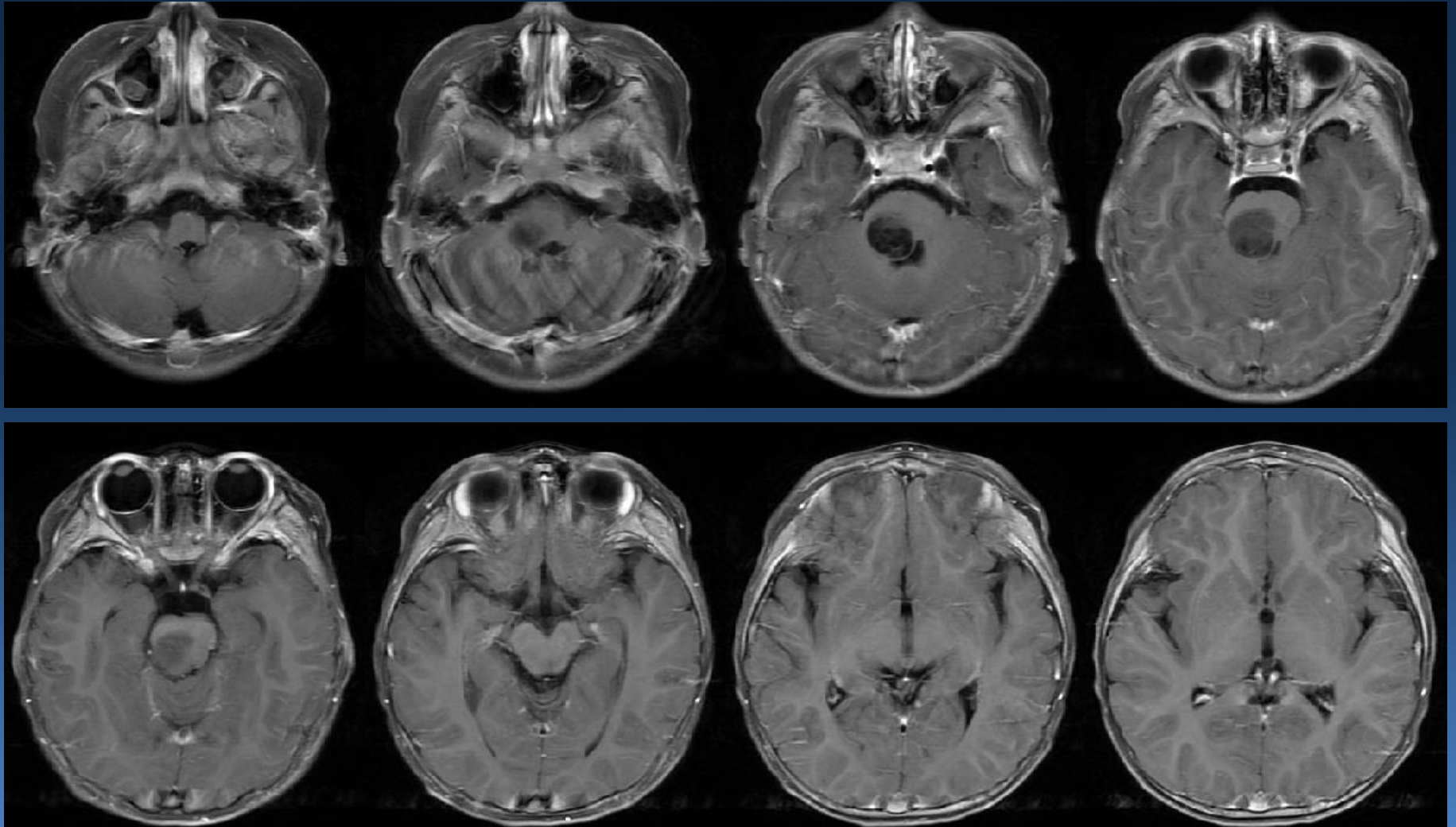
DWI



ADC map



Gd enhanced-FS-T1WI

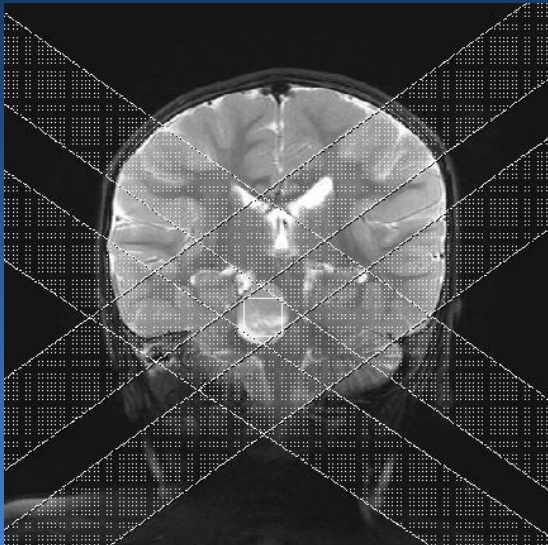
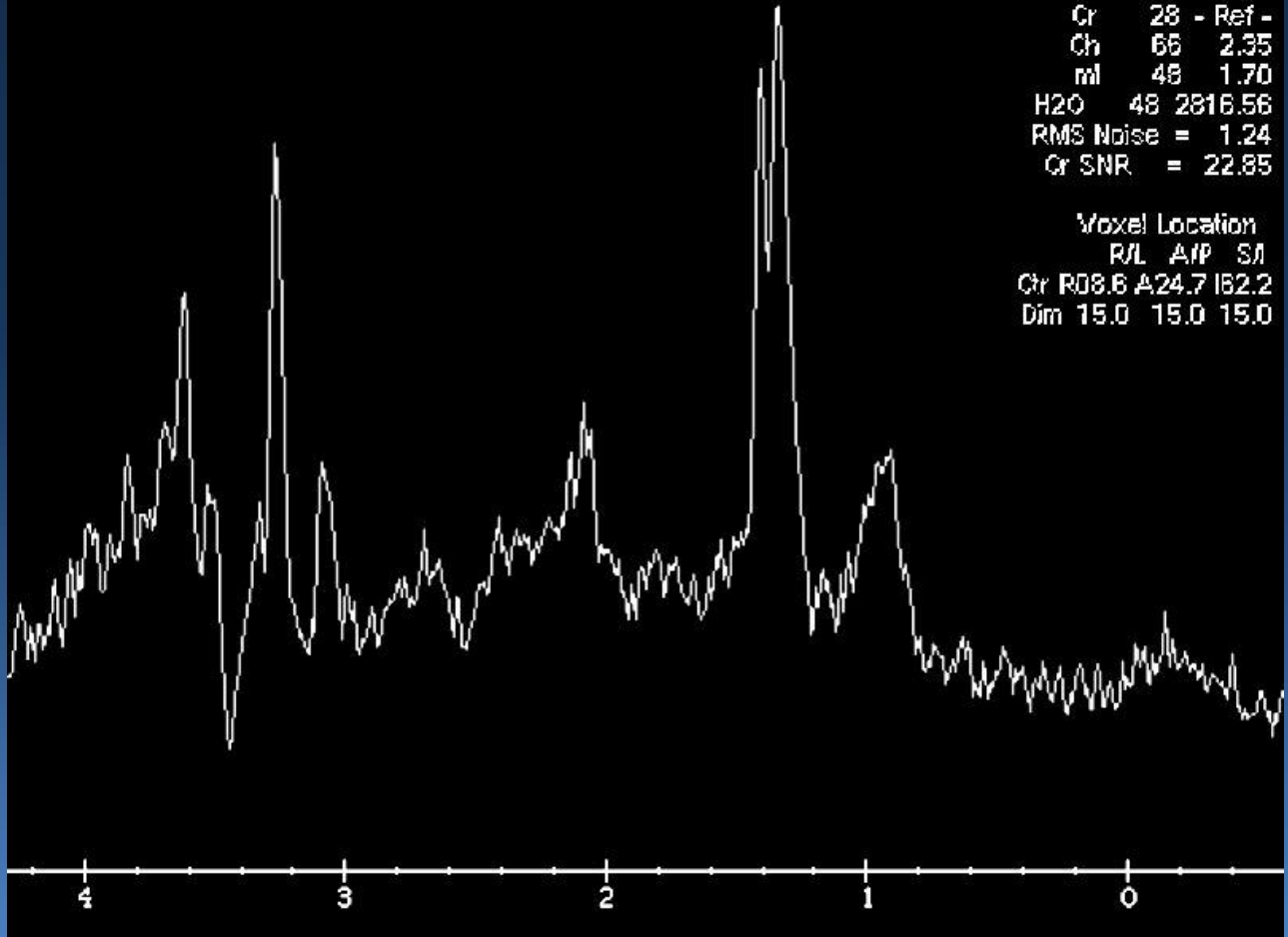


Proton MR Spectroscopy

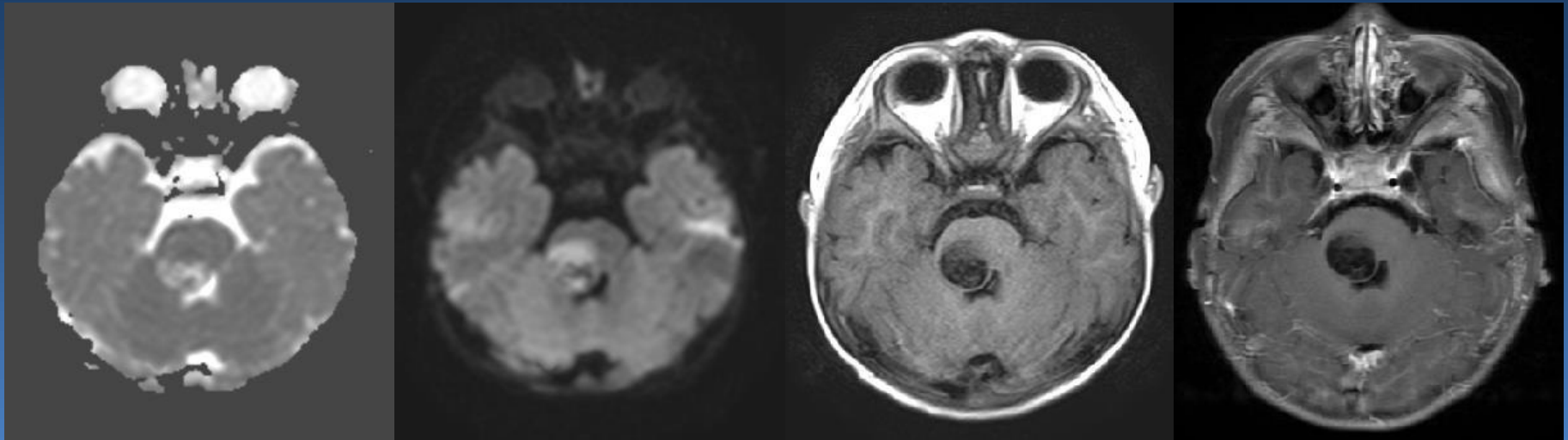
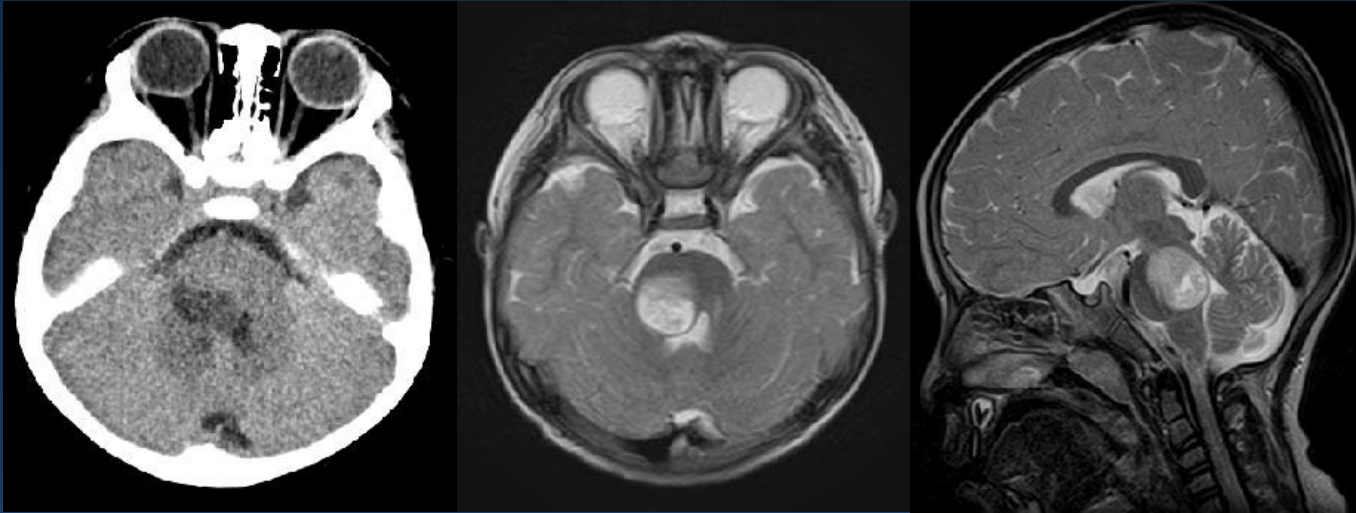
PROBE-P
TR:2000
TE:30.0

Mach. #	Ratio
NA ????????	Void
Cr 28	- Ref -
Ch 66	2.35
ml 48	1.70
H2O 48	2816.56
RMS Noise = 1.24	
Cr SNR = 22.85	

Voxel Location			
R/L	A/P	S/I	
Cr R08.6	A24.7	I62.2	
Dim 15.0	15.0	15.0	

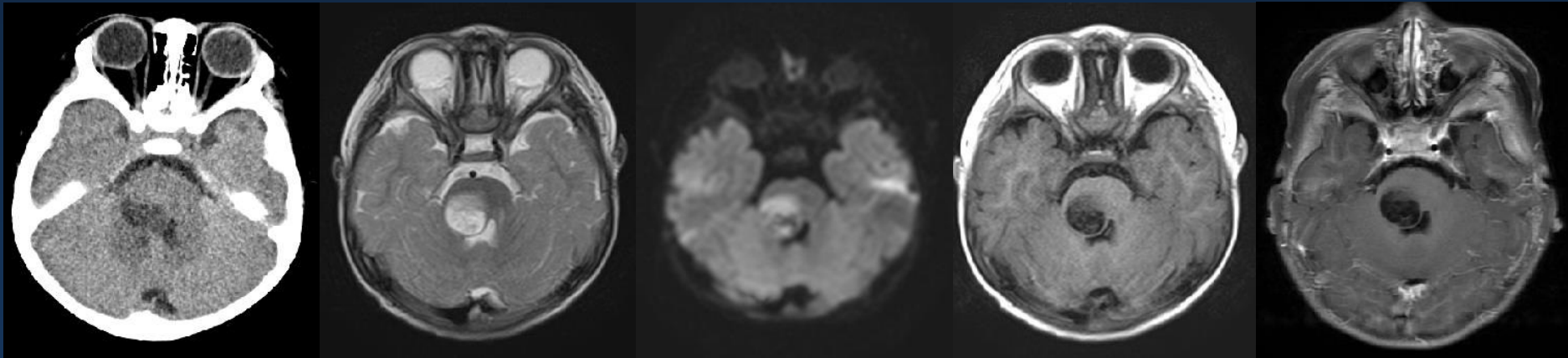


Diagnosis please





Imaging findings

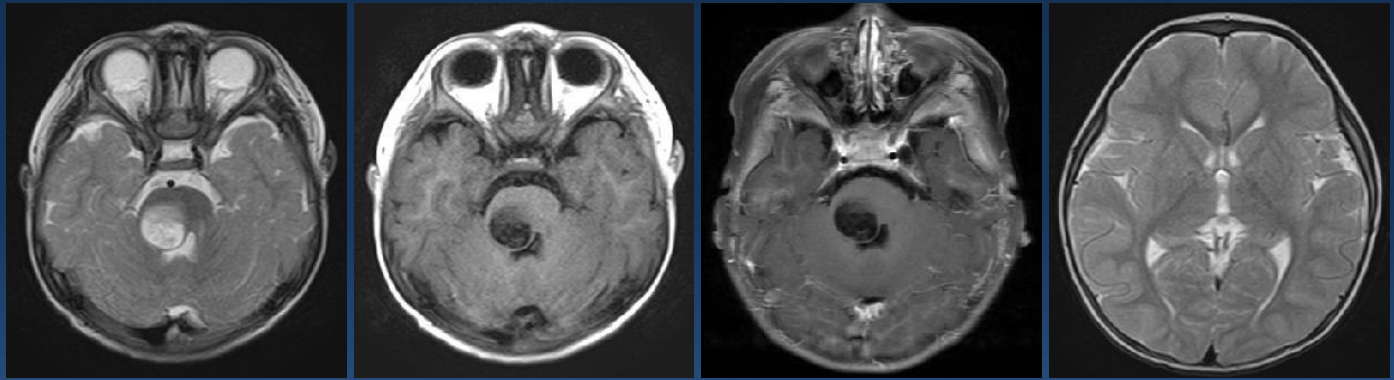


- Circumscribed mass without peritumoral edema in the right side of pons
- CT: large iso-low mixed density with small high density area
- MRI:
 - T2WI: mixed high SI
 - T1WI: mixed low SI
 - CE-T1WI: no enhancement
 - DWI: high SI area (ADC value: lower~equal to brain parenchyma)
 - MRS: Cho \uparrow , NAA \downarrow , Cre \downarrow , Cho/NAA ratio \uparrow , lactate·lipids \uparrow

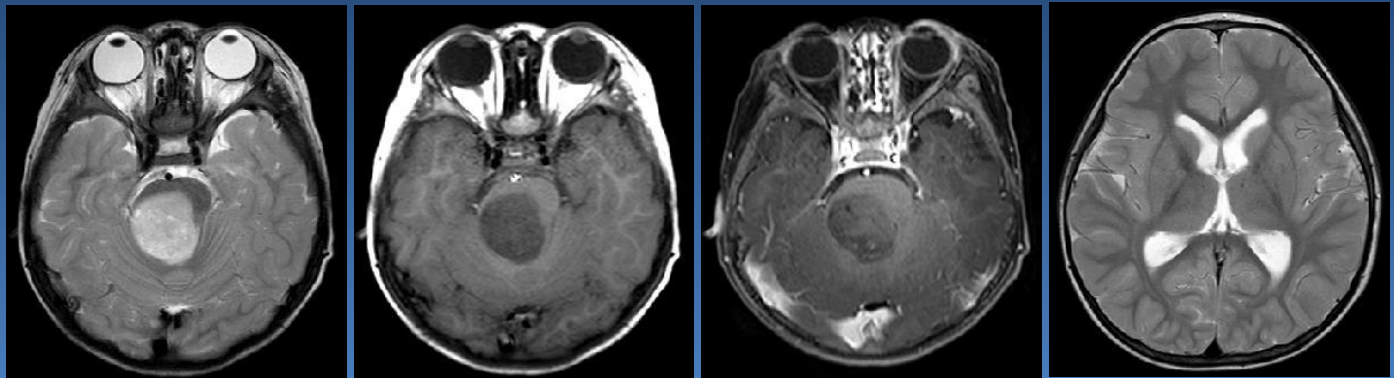
Clinical course

- After second opinion, he transferred to Osaka City University for treatment.
- On MRI after a month, enlarged tumor showed tiny enhancement and developed obstructive hydrocephalus.
- Tumor was resected.

MRI
at first time

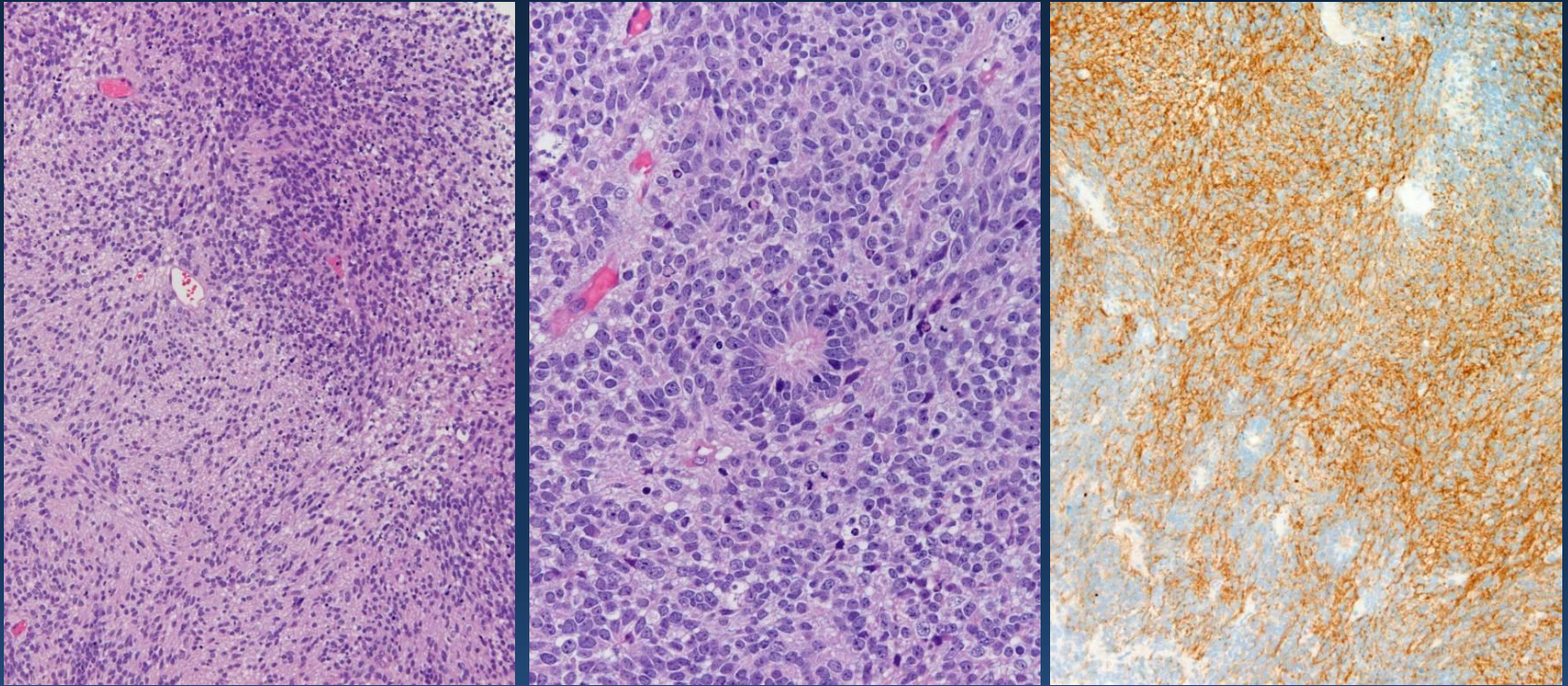


MRI
after a month



謝辞：下野 太郎 先生（大阪市立大学）
経過画像と臨床情報を提供くださり、感謝申し上げます。

Pathological findings



細胞密度の高い領域と低い領域が斑状に混在。細胞密度が高い領域は、クロマチンに富む類円形核を有し、細胞質が不明瞭な小型細胞がびまん性高密度に増殖。細胞密度が低い領域では、背景に繊細な線維性基質が多量に認められ、これらは細網状でニューロピルに類似している。

両者の中間像を示す領域に複数のependymoblastic rosetteが形成されている。synaptophysinは背景の線維性基質に強陽性で、少数の腫瘍細胞も陽性。

謝辞：平戸 純子 先生（群馬大学）

病理組織スライドを提供くださり、感謝申し上げます。

Diagnosis

CNS primitive neuroectodermal tumor
(PNET)

Embryonal Tumor
with Abundant Neuropil and True Rosettes
(ETANTR)

ニューロピルと真性ロゼットに富む胎児性腫瘍

Embryonal neoplasms of the CNS

according to the 2007 WHO classification

according to the 2010 General Rules Clinical and Pathological Studies on Brain Tumors in Japan

- Medulloblastoma
- CNS primitive neuroectodermal tumor (PNET)
 - Medulloepithelioma
 - Ependymoblastoma
 - CNS neuroblastoma
 - CNS ganglioneuroblastoma
 - ETANTR
 - In 2000, Eberhart et al. first described.
- Atypical teratoid rhabdoid tumor (AT/RT)

Items	ETANTR
Pathological findings	Undifferentiated neuroepithelial cells, abundant well-differentiated neuropil, and ependymoblastic rosettes abruptly arising from paucicellular regions of neoplastic neuropil
A peak age of onset	mostly under 4 years of age
Sexual predominance	Female predominance (M:F=1:2) In other CNS embryonal tumors, males outnumber females or the percentage of the two is roughly equal.
The relative incidence	Not clear (Rare)
Preferential location	Frontal lobes or posterior fossa
Current treatment	Tumor resection, Systemic chemotherapy, Radiation
Prognosis	Extremely poor (WHO grade IV) Median survival: only 9 months

Radiological findings of ETANTR

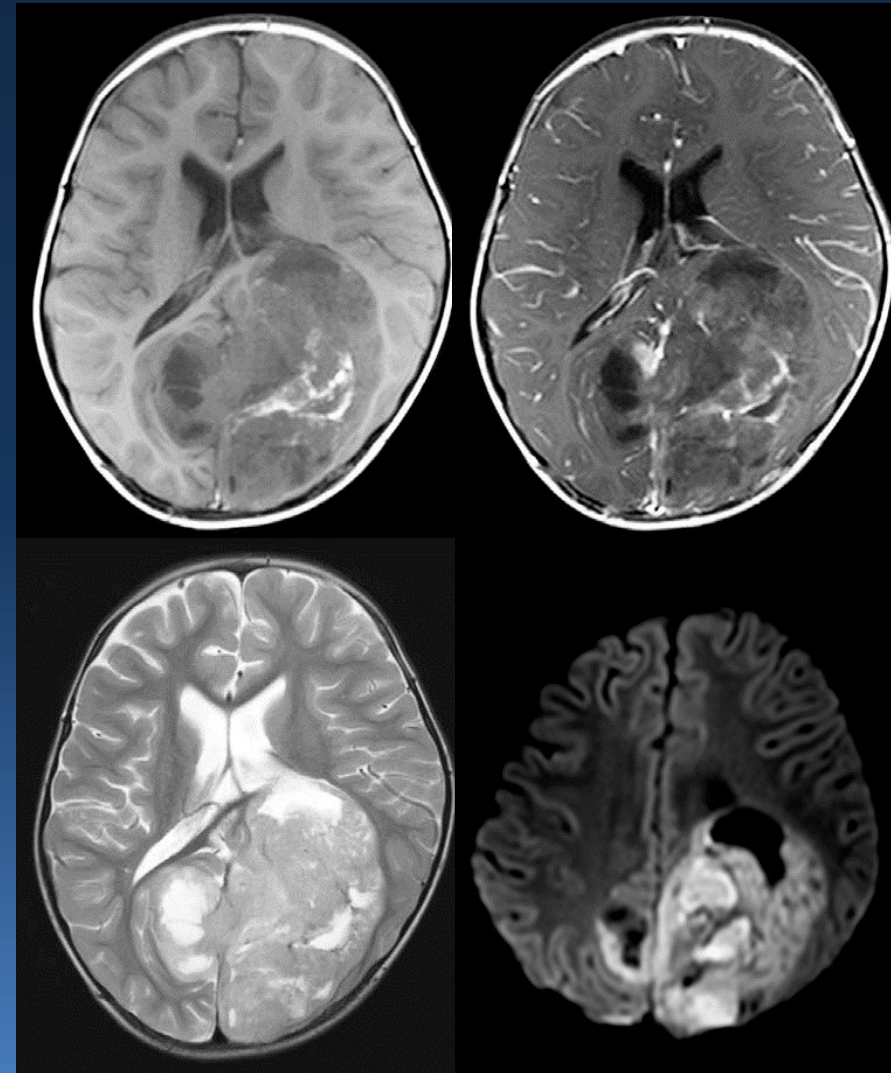
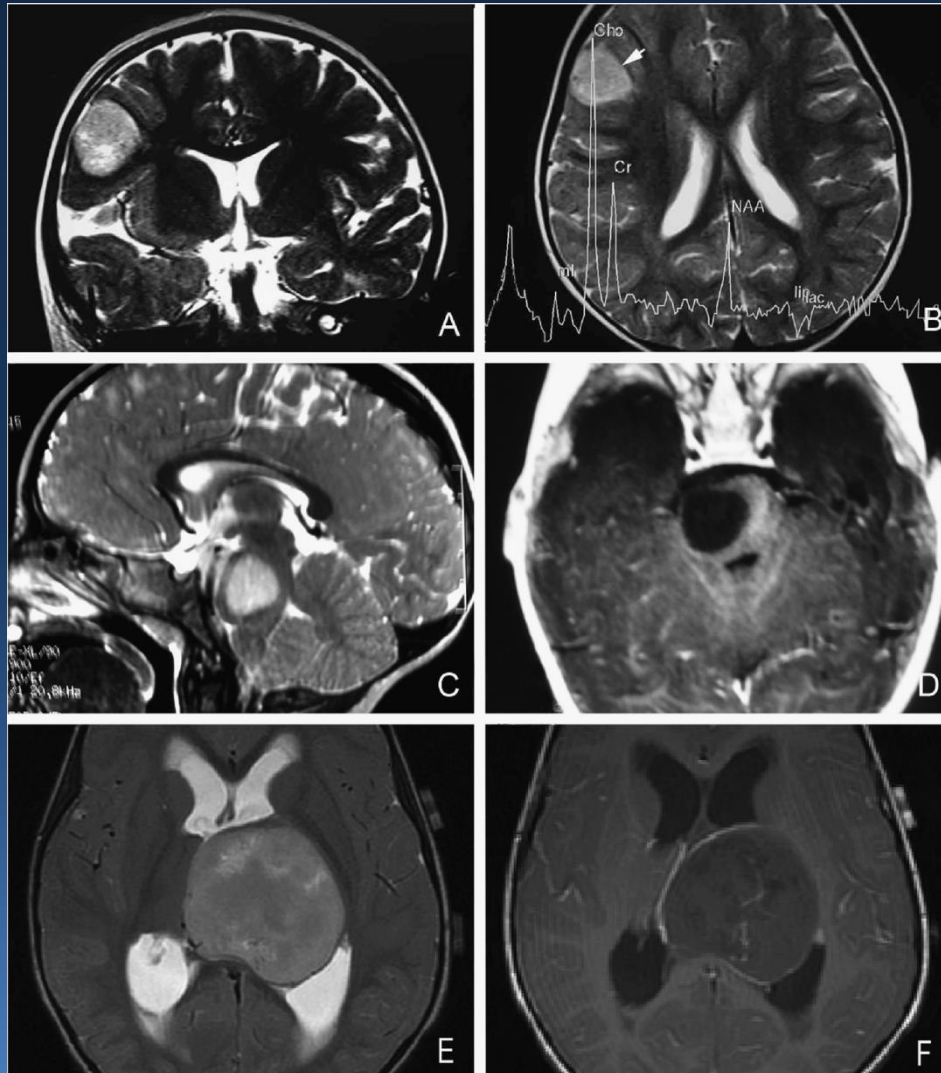
- Well-demarcated, little edema
- Hyperintensity on T2WI
- ADC value: low
- Focal enhancement or no enhancement in contrast to most CNS PNET
- MRS:
 - Choline peak
 - A high ratio of Cho/NAA: suggesting hypercellularity
- Imaging findings are indistinguishable from those of other PNETs.
 - Necrosis, Hemorrhage, Calcification, CSF dissemination

Anne G Osborn. Osborn's BRAIN. Lippincott Raven 2012

Marco Gessi, et al. Am J Surg Pathol 2009;33:221-217

Belen Ferri Niguez, et al. Childs Nerv Syst 2010;26:1003-1008

Other cases of ETANTR



Marco Gessi, et al. Am J Surg Pathol
2009;33:211-217

第32回 神経放射線ワークショップ
九州大学 菊地一史先生 提示症例